

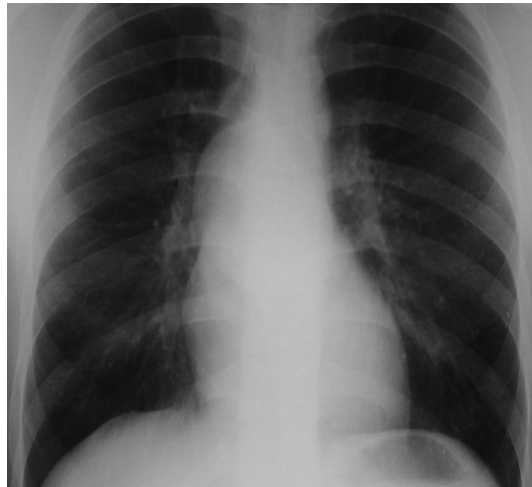
CASE REPORT

Gamal Rabie Agmy

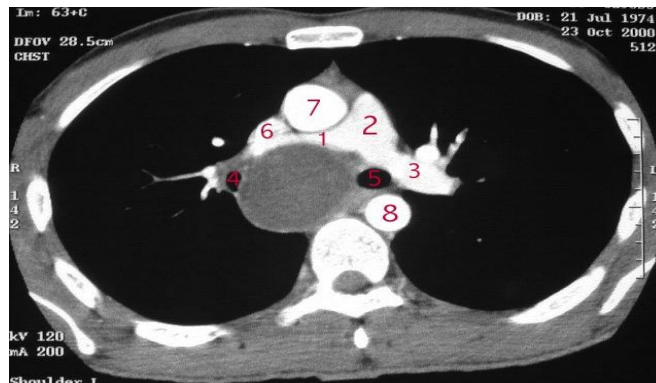
Prof. of chest diseases, Assiut University, Egypt

Email: gamalrabie20002000@yahoo.com

A 28 years old male presented to chest department of Assiut University by 1 year history of central chest discomfort. There were no other symptoms; the patient had no past medical history and was not under medications. He has been life-long a non-smoker. On examination, the patient looks well. There was no evidence for clubbing or lymphadenopathy. The respiratory examination was normal as well as the abdominal examination. Chest radiography was performed.



CT chest was the next investigation.



Would you please now identify the structures labelled 1 –8 on the CT scan image?
According to CT, what is your diagnosis?
Please suggest the treatment of this case.

ANSWER

Bronchogenic Cyst

Mediastinal cyst is usually in middle mediastinum; always in close relation to tracheobronchial tree. Usually asymptomatic and does not need any specific intervention.

Structures labeled:

- 1-Right pulmonary artery
- 2-Pulmonary trunk
- 3-Left pulmonary artery
- 4-Right main bronchus
- 5-Left main bronchus
- 6-Superior vena cava
- 7-Ascending aorta
- 8-Desending aorta